Original Article

# Inferior Turbinate Hypertrophy Histopathology in Allergic Rhinitis Patients and in Patients with Deviated Nasal Septum

*Mohamed Kamel Al Awad[1] and Mohamed Yusef Ali[2]*

*[1]Department of Otorhinolaryngology, [2]Deprtment of Pathology, Faculty of Medicine, Al Azhar University, Egypt*

## ABSTRACT

**Background:** A common issue in otorhinolaryngology is nasal obstruction based on by inferior turbinate hypertrophy (ITH).

**Objective:** In order for the surgeon to choose the most appropriate surgical procedure, it is important to distinguish between compensatory ITH caused by DNS and ITH caused by allergic rhinitis.

**Patients and Methods:** There were 60 patients in this study, and their ages ranged from 18 to 50. (28 male & 32 female ). Their history, endoscopic examination, and CT scans of their Para nasal sinuses all indicated that they had ITH. There were two groups of patients. Group A: This group, which consisted of 30 patients with compensated ITH brought on by DNS, underwent a skin prick test to weed out any allergic patients. Group B was composed of 30 patients who had bilateral ITH brought on by allergic rhinitis. Under general anesthesia, all patients underwent endoscopic partial inferior turbinectomy with or without septoplasty, being careful to remove all three layers of the turbinate. The Department of Pathology handled the turbinate specimens according to protocol, and slides were made and analyzed histopathologically and microscopically.

**Results:** The bony layer's mean thickness of ITH cases in group A was 6.50 ±1.75mm, whilst its thickness in group B was 2.25 ± 1.25 mm with statistical significant *P value* =0.001.

**Conclusion:** The bone layer leads to the majority of the compensatory ITH thickness caused by DNS, hence it should be the focus of surgery using the right surgical method.

**Key Words:** Allergic rhinitis, deviated nasal septum, histopathology, inferior turbinate hypertrophy.

**Received:** 27 May 2022, **Accepted:** 28 July 2022

**Corresponding Author:** Mohamed Kamel Al Awady, MD, Department of Otorhinolaryngology, Faculty of Medicine, Alazahar University, Egypt, **Tel.:** +20 10 0225 5375, **E-mail**: mohamedkamel292@yahoo.com

**ISSN:** 2090-0740, 2022

## INTRODUCTION

The inferior turbinate (IT) plays a vital function in nose physiology by regulating the temperature and humidity of inhaled air, and also filtering foreign particles through the mucociliary clearance system[1]. Various factors, notably allergic rhinitis, non-allergic (vasomotor) rhinitis, and rhinitis medicamentosa, can lead to considerable IT hypertrophy[2].

When the nasal septum deviates to one side, the inferior turbinate fills the extra space in the contralateral nasal cavity[3]. It is believed that this counter balanced mechanism, which may be identified by compensatory hypertrophy, evolved to protect the more patent nasal side from elevated air flow and its drying and crusting effects[4].

Advocates of concomitant turbinate surgery during septoplasty claimed that hypertrophy involves both mucosal elements and conchal bone, so alterations are not spontaneously reversible throughout septal surgery and should be corrected to avoid obstruction on the septal deviation's opposite side after septal correction[5,6]. When medical treatment fails to result in a considerable improvement of nasal blockage, surgical decrease of the hypertrophic inferior turbinate has been proposed[7,8].

A variety of reduction procedures have been devised throughout the years with the goal of enhancing nasal airway passages, maintaining organ function, and avoiding preoperative bleeding and long-term complications[9].

The decision to perform inferior turbinectomy should be predicated not only on the clinical manifestations but also on the organ's morphometric characteristics[10]. This is the first morphometric investigation to cover ITH size, composition, and potential pathogenic alterations. Such data can help the otolaryngologist to choose which type of turbinate reduction surgery (sub mucous diathermy or partial turbinectomy) is suitable[11,12].

## AIM OF THE WORK

This study's aim was to supply qualitative and quantitative data on ITH's different soft tissue and bone constituents so that the surgeon could select the best surgical procedures.

 *DOI: 10.21608/ejentas.2022.141170.1518*

## PATIENTS AND METHODS

The study was done from May 2020 to October 2021. This was a prospective study conducted between May 2020 and October 2021 at department of Otolaryngology, Al-azhar University Hospitals. The study included 60 patients complaining of nasal obstruction as the main symptom as proven by history and examination.

This study was accepted by medical ethical committee of Al-Azhar University. All cases were informed and a written consent was gathered from all cases. Patients were sub-categorized into two groups. In group A: 30 cases were featured by compensated inferior turbinate hypertrophy due to septal deviation. In group B: 30 patients were presented by bilateral inferior turbinate hypertrophy owing to allergic rhinitis and mean age of group A was 43±15 years old with a range of 22-58 years old and mean age of group B was 35.27 ± 9.51 years old with a range of 18-55 years old. In this study, in group A, male patients were 21 cases (69.3%) and female patients were 9 cases (30.7%) & in group B, male patients were 19 cases (63.7%) and females' patients were 11 cases (36.3%).

### *Inclusion criteria*

1. presence of nasal obstruction due to either turbinate hypertrophy of allergic rhinitis or deviated nasal septum
2. No response to medical treatment

### *Exclusion criteria*

1. Patients with other reasons of nasal obstruction including nasal granuloma, Sino-nasal polyposis, or neoplasm of the nose and Para nasal sinuses.
2. patients with vasomotor or non allergic rhinitis
3. Patients <18 years old.
4. Patient refuse or unfit for surgery

All patients were subjected to:

- Questionnaire concerning side, type and duration of nasal obstruction and linked symptoms including headache, nasal discharge, epistaxis sneezing and degree of response to medical treatment.
- Rigid nasal endoscopy was preoperatively performed to detect turbinate hypertrophy either unilateral (compensated due to septal deviation) or bilateral pale bluish hypertrophied turbinate (due to allergic rhinitis)

CT scan of Para nasal sinuses were done to all patients preoperatively to confirm the diagnosis of nasal problem which are turbinate hypertrophy due to allergic rhinitis (Figure 1) or deviated nasal septum (Figure 2) and exclude any sinus opacity and other causes of nasal obstruction.

**Fig. 1:** CT scan of Para nasal sinuses of allergic rhinitis patient showing bilateral inferior turbinate hypertrophy

**Fig. 2:** CT scan of Para nasal sinuses showing deviated nasal septum and compensatory inferior turbinate hypertrophy on the other side

Skin prick test (SPT) was performed for all group A's cases (compensated ITH due to septal deviation) to exclude allergic patients. SPT was performed by injecting allergens such as housefly particles, house dust, house dust mites, mixed pollens, combined molds, cotton dust, and grass pollens into the patient's forearm. The biggest diameter of the wheal in each test is recorded. A positive results wheal is ≥ 3 mm. then the patient who had positive skin prick test was excluded from this study

- Pre-operative routine investigations, CBC, coagulation profile and liver and kidney functions.
- All patients provided informed consent prior to surgery.
- All cases were submitted to an endoscopic partial inferior turbinectomy with or without septoplasty under general anesthesia. Throughout the procedure, all layers of the turbinate were removed, the turbinate architecture was maintained by delicate control, and care was made not to injure the mucosal layer.
- All patients were evaluated postoperatively for problems such as bleeding, crusting, synechia, infection, and subjective improvement in their symptoms.
- Follow-up visits were scheduled 1, 3 and 6 months after surgery. During each visit nasal examination was performed by rigid nasal endoscopy

### *Tissue Preparation and Measurements*

The turbinate specimens were promptly fixed in 10% buffered formalin, decalcified with 14% neutral EDTA (ethylenediamine tetraacetic acid), and dehydrated with elevating ethanol concentrations. The specimens were immersed in paraffin blocks, and four-micron thick sections were cut perpendicular to the mucosal surfaces from the blocks. Hematoxylin and eosin (H & E) stained sections were histologically examined. The IT's overall thickness, and also the medial mucosal layer, bone layer, and lateral mucosal layer's thickness, were measured with a calibrated eyepiece mounted to a microscope at x40 magnification.

The condition of venous sinusoids, submucosal glands and inflammatory cells infiltrate as lymphocytes, plasma cells and eosinophils in each group was also studied.

### *Statistical analysis*

The Statistical Program for Social Science (SPSS) version 20.0 was utilized to analyze the data. For quantitative analysis, the t-test was utilized. For qualitative data analysis, the Chi-square test was applied. The following tests were done:

- $\chi 2$ test of significance was utilized in order to contrast proportions between two qualitative factors.
- When the allowed error margin was set to 5% and the confidence interval was 95%, the P value was deemed significant as the following:

### *P value*

1. *P value* lower than or equal to 0.05 was deemed significant.
2. *P value* lower than or equal to 0.001 was deemed as highly significant.
3. *P value* higher than 0.05 was deemed insignificant.

## RESULTS

The study was performed from May 2020 to October 2021. Mean age of group A was 43±15 years old with a range of 22-58 years and mean age of group B was 35.27 ± 9.51 years old with a range of 18-55years. In this study, in group A, male patients were 21 cases (69.3%) and female patients were 9 cases (30.7%) & in group B, male patients were 19 cases (63.7%) and female patients were 11 cases (36.3%). There was no significant difference between the two groups regarding age and sex distribution (*p-value* >0.05).

The Patients in the present study were subcategorized into two groups:

**Group A** involved 30 cases (50%) diagnosed to have ITH secondary to deviated septum (compensatory hypertrophy).

**Group B** included 30 cases (50%) had allergic rhinitis and related ITH.

There was no statistically significant difference between both groups as per preoperative clinical manifestations (*p-value*>0.05) (Table1).

In the present study, results of micrometric study showed that the mean total thickness of ITH in group A was 10.25±2.50mm and in group B was 7.25±2.75mm with a non-statistical significance (*p value*>0.05). (Table. 2)

Also, the bony layer's mean thickness (BL) in ITH cases with a deviated nasal septum (group A) was 6.50 ±1.75mm, whilst its thickness in the allergic rhinitis group (group B) was 2.25 ± 1.25mm with a statistical significance (*p value*<0.05).(Table 2)

Table(2): Total thickness of the ITH and thickness of Bony layer (BL) in both groups

**Table 1:** Clinical manifestations in both groups

| | nasal obstruction | Headache | Epistaxis | nasal discharge | $\chi 2$ | *p.value* |
|---|---|---|---|---|---|---|
| Group A | 30 patients (100%) | 20 patients (66.6%) | 14 patients (46.6%) | 18 patients (59.4%) | 5.132 | 0.327 |
| Group B | 30 patients (100%) | 14 patients (46.6%) | 6 patients (19.9%) | 26 patients (86.6%) | | |

**Table 2:** Total thickness of the ITH and thickness of Bony layer (BL) in both groups

| | | Group A | Group B | $\chi 2$ | *P. value* |
|---|---|---|---|---|---|
| Total thickness | Mean ± SD<br>Median (Min. – Max.) | 10.25±2.50 mm<br>9.75 (7.5– 12.75) | 7.25±2.75mm<br>8.25 (4.25 – 10.5) | 9.62 | 0.204 |
| Bony layer(BL) (mm) | Mean ± SD<br>Median (Min. – Max.) | 6.50 ±1.75mm<br>5.75 (3.5– 8.15) | 2.25 ± 1.25mm<br>2.75 (1.5– 3.75) | 17.15 | 0.0382 |

### *χ2(Chi-square test)*

The medial mucosal layer's mean thickness (MML) in ITH cases with a deviated nasal septum (group A) was 3.25±0.5 mm, whilst its thickness in the allergic rhinitis group (group B) was 4.25 ±0.75mm with a non-statistical significance (*p value*>0.05). (Table 3) (Figures 3 ,4)

The lateral mucosal layer's mean thickness (LML) in ITH cases with a deviated nasal septum (group A) was 1.25 ±0.25mm, whilst its thickness in the allergic rhinitis group (group B) was 1.75 ±0.75mm with a non- statistical significance (*p value*>0.05). (Table 3) (Figures 3 ,4)

**Table 3:**Thickness of medial and lateral mucosal layer in mm of ITH in both groups

| | | Group A | Group B | χ2 | *P. value* |
|---|---|---|---|---|---|
| Medial mucosal Layer(MML) by mm | Mean ± SD<br>Median (Min. – Max.) | 3.25 ± 0.5mm<br>2.75 (0.25– 4.25) | 4.25 ± 0.75mm<br>3.15 (0.50– 5.75) | 3.72 | 0.061 |
| Lateral mucosal Layer(LML) by mm | Mean ± SD<br>Median (Min. – Max.) | 1.25 ±0.25mm<br>0.7 5 (0.15– 2.25) | 1.75 ± 0.75mm<br>1.25 (0.25– 2.25) | 2.82 | 0.174 |

χ2(Chi-square test)

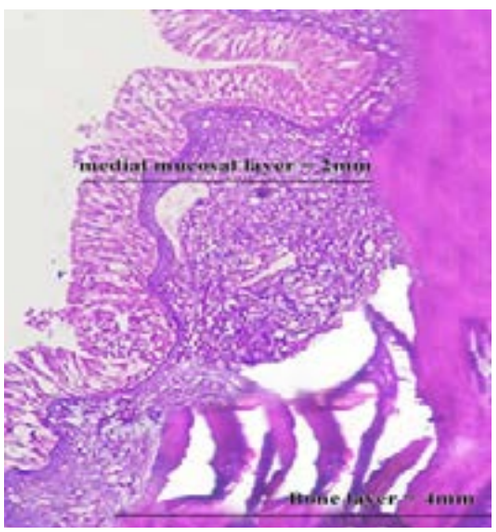


**Fig. 3:** Micrometric image of compensated ITH of DNS showing thickening of BL is more than MML

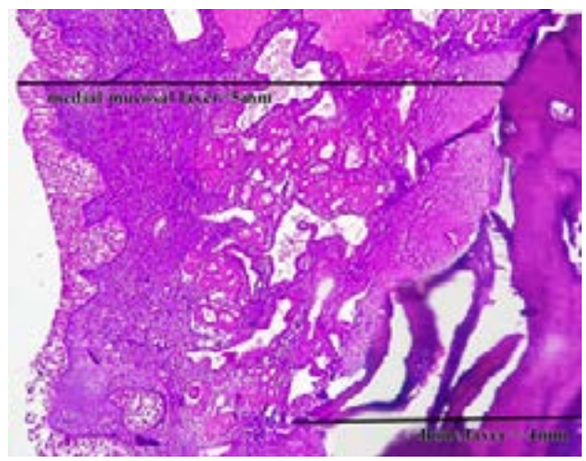

**Fig. 4:** Micrometric image of ITH of allergic rhinitis showing thickening of BL is less than MML.

The ITH's thickness and the circumstances of the venous sinusoids in each group were also investigated in this study. Lymphocytes, plasma cells, and eosinophils were the most prominent inflammatory cells in the allergic rhinitis group and venous blood sinusoids less prominent. (Figure 5), whilst lymphocytes and plasma cells were less prominent inflammatory cells in compensatory ITH group with a deviated nasal septum, and venous blood sinusoids were prominent. (Figure 6), This study's specimens exhibited no dysplasia, malignant alterations, or chronic granulomatous abnormalities.

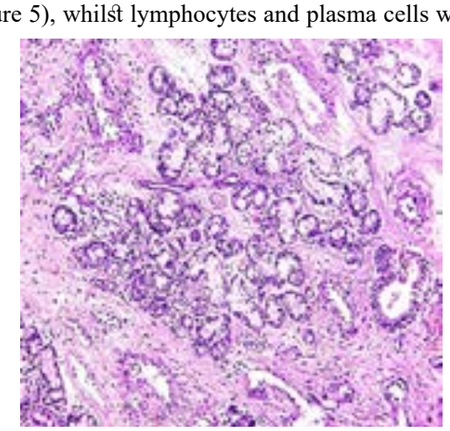

**Fig. 5:** histopathological pictures of ITH of allergic rhinitis shows proliferating mucous secreting glands with marked eosinophilic inflammatory infiltrate

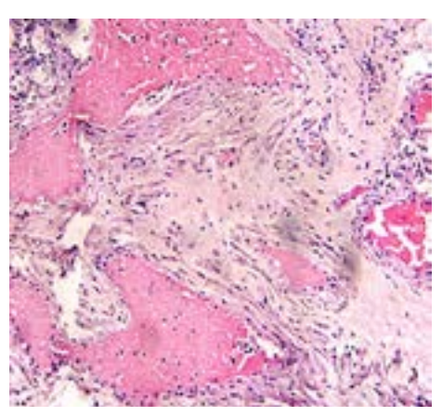

**Fig. 6:** histopathological pictures of compensated ITH of DNS shows dilated congested blood vessels with little inflammatory cells infiltrate (H&E x100).

The postoperative issues were evaluated. Crusting was observed in two (13.3%) patients in group A. The use of nasal alkaline douching was recommended to the patients. Synechia developed in two patients (10%) following turbinectomy and septoplasty. Under local anesthetic, Synechia was released.

This study found that: The bone layer leads to the majority of the compensatory ITH thickness caused by DNS, hence it should be a surgical target with correct surgical technique selection, such as sub mucous diathermy, which would not relieve this patient's nasal blockage.

Mucosal layers, on the other hand, contribute to the major thickness of the turbinate in cases with allergic rhinitis. As a result, surgical procedures such as Sub-mucous diathermy, which aims to eliminate the mucosa while leaving the bony component of the turbinate intact, are appropriate for such individuals.

## DISCUSSION

In the current study, an overallof 30 cases with ITH were chosen (18 male and 12 female) aged between 18 and 50 years old. Assessment of which type of turbinate hypertrophy was depending on: History, clinical examination, and endoscopic examination.

The clinical outcome of histological characteristics of the ITH and consequences of partial inferior turbinectomy in allergic rhinitis and deviated nasal septum were studied in this study.

In the present study, the results of micrometric histopathological study showed that the thickness of BL in compensated ITH group (group A) was 6.50 ±1.75mm, whilst its thickness in the allergic rhinitis group (group B) was 2.25 ± 1.25mm with a statistical significance (*P value* =0.001).

This study is similar to the study of Mohamed A *et al*., 2014, they showed that the BL's thickness was 11.25 ± 2.75 and 5.5 ± 2.5 mm in compensated ITH cases with DNS and in the allergic rhinitis group consecutively. Additionally, in their study, the average MML thickness was 8.5 ±3.5 mm in compensated ITH patients with DNS, contrasted to 9.5 ±3.5 mm in the allergic rhinitis group, and the average LML thickness was 6.25 ±2.25 mm in patients with DNS and 7.5 ±3.5 mm in the allergic rhinitis group[13].

In study of Berger *et al*., 2006 who demonstrated that MML's mean thickness, bony layer and LML was 1.76±0.26mm, 1.03±0.54mm and 1.03±0.36mm consecutively in control group and it was 1.87±0.37mm, 2.03±0.50mm and 1.26±0.38mm consecutively in DNS with ITH. Additionally, they noted in their study that in cases of ITH with DNS, the bone layer of the turbinate's hypertrophy outperforms other layers and accounts for 3/4 of the inferior turbinate's whole growth[14].

Berger *et al*. 2006 and Mohamed A *et al*. 2014 concluded that hypertrophy of BL in ITH patients with DNS is more than hypertrophy of mucosal layer, As a result, the bone layer should be a surgical target with correct surgical technique selection, such as submucous diathermy, which will not relieve these patients' nasal obstruction.

Also, this study showed that the mean thickness of MML of compensated ITH group (group A) was 3.25±0.5 mm, whilst its thickness in the allergic rhinitis group (group B) was 4.25 ±0.75mm with a non-statistical significance (*P value* =0.06) and the mean thickness of LML in compensated ITH group (group A) was 1.25 ±0.25mm, whilst its thickness in the allergic rhinitis group (group B) was 1.75 ±0.75mm with a non-statistical significance (*P value* =0.17). This finding is in line with those of Hadar T. *et al*. (2005), who revealed that the medial mucosal layer's considerable enlargement plays a key role in how the nasal blockage is perceived due to chronic allergic irritation, and that alleviation from the obstruction predominantly needs decrease of this layer[15].

Also, this finding is in line with the findings of Rohrich RJ *et al*. (2001) who stated that sub-mucous diathermy is popular a practice proposed as a medication for ITH of allergic rhinitis specially anterior portion when it contributes to airway resistance[16].

Finally, recognizing the hypertrophic inferior turbinate's histopathology is critical for developing and managing inferior turbinate reduction surgery[17].

## CONCLUSION

This study found that the bone layer leads to the main turbinate thickness in instances of compensatory ITH" owing to DNS and that it should be a surgical target with the right surgical approach, such as submucous diathermy, which would not relieve this patient's nasal blockage.

In contrast, in allergic rhinitis, this study showed the hypertrophy of the mucosa is more than hypertrophy of conchal bone, so the surgical techniques such as sub-mucous diathermy which aims to eliminate the mucosa with leaving the turbinate's bony part are appropriate for such patients.

## CONFLICT OF INTERESTS

There are no conflicts of interest.

## REFERENCES

1. Lund VJ,(2015). Anatomy of the nose and paranasal sinuses. In: Kerr AG, Gleeson M, eds. Scott-Brown's Otolaryngology, n6th ed, vol 1. Oxford: Butterworth-Heinemann,1–30

2. Ballenger JJ, (2012). The nose and accessory sinuses. In: Ballenger JJ, ed. Diseases of the Nose, Throat, Ear, Head, and Neck, 13th ed. Philadelphia: Lea & Febriger:1–25.

3. BRIAN D:The nasal septum. In: Mackay I.S., Bull T.R., editors. Scott-Brown's otolaryngology, Volume 4: Rhinology. 5th ed. Butterworth & Co. Ltd., . Kuopio, Finland: Kuopio University.2017, 154-79.

4. GRAY L.P(2010): Deviated nasal septum: Incidence and etiology. Ann. Otol. RhinolLaryngol., (3, pt 3) (Suppl 50): 3-20.

5. FAIRBANKS D.N.F. and KALINER M(2014): Non allergic rhinitis and infection. In: Cummings C.W., Fredrickson J.M., Harker A.L., *et al*., editors. Otolaryngology-head and neck surgery, Volume 2. 3 rd ed. St. Louis: Mosby, p. 910-20.

6. EGELI E., DEMIRCI L., YAZICI B., *et al*(2011): Evaluation of the inferior turbinate in patients with deviated nasal septum by using computed tomography. Laryngoscope, 114: 113-7.

7. Passali D., Passali F.M., Damiani V., Passali G.C., Bellusi L. (2012):Treatment of inferior turbinate hypertrophy: a randomized clinical trial. Ann Oto Rhino Laryngol., 2003;112:683-688.

8. Hol MK, Huizing EH.(2013):Treatment of inferior turbinate pathology: a review and critical evaluation of the different techniques. Rhinology. 2000;38: 157-166.

9. POLLOCK R.A. and ROHRICH R.J(2015).: Inferior turbinate surgery: An adjunct to successful treatment of nasal obstruction in 408 patients. Plast. Reconstr. Surg., 74: 227-34,

10. Hol MK, Huzing EH Hol MK, Huzing EH. (2016). Treatment of inferior turbinate pathology: a review and critical evaluation of the different techniques. Rhinology;38: 157–166.

11. Romppanen T, CollanY(2013).. Practical guidelines for a morphometric study. In: Collan Y, ed. Stereology and Morphometry in Pathology. Kuopio, Finland: Kuopio University Press, 1984:72–95.

12. Collan Y(2017).. Stereology and morphometry in pathology: an introduction. In: Collan Y, ed. Stereology and Morphometry in Pathology. Kuopio, Finland: Kuopio University Press,5–11.

13. Berger G, Hammel I, Berger R, Avraham S, Ophir D(2000); Histopathology of inferior turbinate with compensatory hypertrophy in patients with deviated nasal septum. The Laryngoscope. 2000; 110:2100-2105

14. Berger G, Gass S, OphirD(2006); The histopathology of the hypertrophic inferior turbinate. Archotolaryngol head neck surg; 132:588-594.

15. Hadar T, Ophir D, Yaniv E, Berger G(2005);. Inferior turbinate arterial supply: histologicanalysis and clinical implications. J Otolaryngol;34:46-50.

16. Rohrich RJ, Krueger JK, Adams WP Jr, MarpleBF(2001);. Rationale for submucous diathermy of hypertrophied inferior turbinates in rhinoplasty: an evolution. PlastReconstrSurg. 2001;108:536-544.

17. Spielberg W(1994);.The treatment of nasal obstruction by submucous resection of the inferior turbinate bone. Laryngoscope. 1924;34:197-203.